



PATIENT

ChaCha Jiao

PRESENTING CLINICAL SIGNS

History: Grade 2/6 heart murmur. Elevated BNP. On Clinacin 25mg tabs twice daily. Assess prior to dental.

SPECIES

Feline

ELECTROCARDIOGRAPHIC FINDINGS

A six lead ECG is available at 25mm/s; 10mm/mV. The average heart rate is 170bpm. The rhythm is sinus in origin, with a p for every QRS complex and vice versa. The P wave morphology is positive with a normal dimension. Normal PR. The QRS morphology is positive with normal dimension. MEA is normal. No ectopic beats, pauses or dysrhythmias observed. ECG diagnosis: Normal sinus rhythm.

BREED

British SH

SEX

Male Neutered

ECHOCARDIOGRAM FINDINGS

2D, m-mode, color flow and doppler imaging is available. The left ventricular wall is normal in dimension. There is a mildly hyperechoic endocardium. The papillary muscles are mildly remodeled and hyperechoic. The endocardium also appears remodeled. The left atrium is prominent. The right atrium is normal in size. The right ventricle appears normal. The mitral valve is normal in structure and mobility. No MR or TR. Blood flow through both the LVOT and RVOT is normal in velocity. No pleural or pericardial effusion seen. No obvious cardiac tumors.

AGE

2 years

CARDIAC CHART

WEIGHT

10.1lbs

FELINE CARDIAC PARAMETERS	BODY WEIGHT (kg)	HR (BPM)	IVSd (cm) (Moise, Pipers)	LVIDd (cm) (Moise, Pipers)	LVWd (cm) (Moise, Pipers)	FS (%)	EF (%)
NORMAL PARAMETER	-----	150-240	0.35-0.55	<2 (mean 1.5)	3.5-0.55	35-67	80-100
PATIENT	4.5	NM	0.45	1.4	0.47	47	90
FELINE CARDIAC PARAMETERS	LA/AO (Boon)	LA/AO HEART BASE (Swe) (Abbott)	LA 2D short axis Base view (cm) (Abbott)		LVOT VEL (m/s)	RVOT VEL (m/s)	E max (m/s)
NORMAL	<1.5	<1.3	<1.2		<1.6	<1.3	<0.9
PATIENT	1.2	1.3	1.2		1.1	1.0	NM

INTERPRETED BY

Maggie Machen Lamy,
 DVM DACVIM
 (Cardiology)

IMAGING PERFORMED BY

Amanda Stewart

HOSPITAL NAME

Creditview Eglinton
 Animal Hospital

REFERRING VET

Dr. Ghobrial

INVOICE

46599

DATE

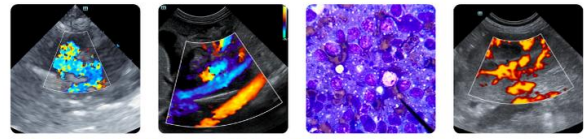
1/28/26

INTERPRETATION OF THE FINDINGS & FURTHER RECOMMENDATIONS

Overtly normal cardiac structure and function. No obvious pathology is appreciated with normal wall thickness and only slight LA enlargement for this signalment. Flow through the great vessels is normal and no additional issues are identified. No cause for the murmur is identified suggesting a physiologic origin is likely. The ECG is unremarkable with a normal sinus rhythm.

Given these findings, no medications are indicated.

No obvious structural cause for BNP elevation is seen here. A flaw of the BNP test is false positives, which is likely the case in a young cat; however, reassessing this patient in 12 months is recommended to ensure early disease was not missed.



PATIENT

ChaCha Jiao

SPECIES

Feline

BREED

British SH

SEX

Male Neutered

AGE

2 years

WEIGHT

10.1lbs

INTERPRETED BY

Maggie Machen Lamy,
DVM DACVIM
(Cardiology)

IMAGING PERFORMED BY

Amanda Stewart

HOSPITAL NAME

Creditview Eglinton
Animal Hospital

REFERRING VET

Dr. Ghobrial

INVOICE

46599

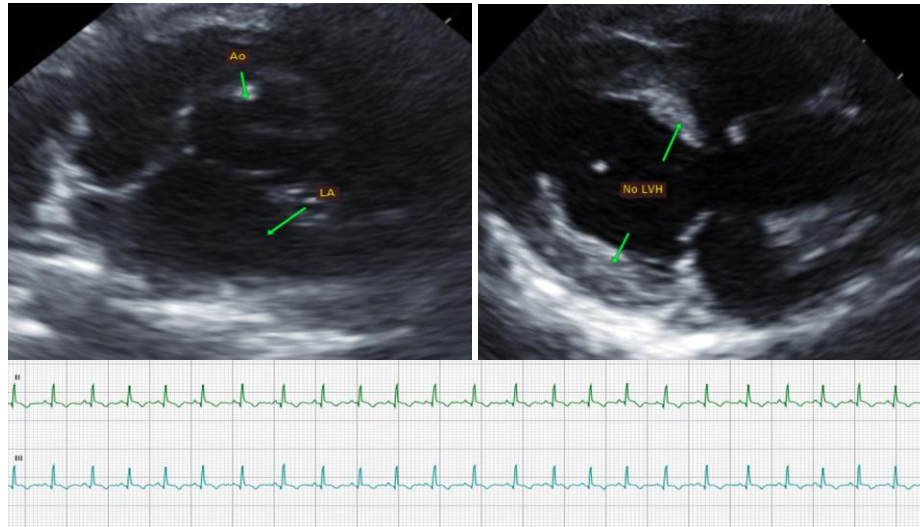
DATE

1/28/26

No cardiac contraindication for general anesthesia. Risk for complication with steroid use typically follows LA dilation, which in this case is low. That being said, any cat can experience unexpected signs of intolerance and monitoring of RR/RE is advised particularly in the initiation phase.

Recommend recheck echocardiogram in 1 year to assess for any progressive issues.

IMAGES



The information and recommendations provided are based on the images presented by the referring veterinarian. No evaluation can be communicated regarding pathology that was not visible in the image/video clips provided.

Thank you for this referral. This report was generated using transcription software, and minor dictation errors may be present. If the clinical or image interpretation does not parallel your findings or if I can be of any further assistance, please contact me.

Maggie Machen Lamy, DVM
Diplomate of the American College of Veterinary Internal Medicine (Cardiology)
info@sonopath.com



PATIENT

ChaCha Jiao

SPECIES

Feline

BREED

British SH

SEX

Male Neutered

AGE

2 years

WEIGHT

10.1lbs

INTERPRETED BY

Maggie Machen Lamy,
DVM DACVIM
(Cardiology)

**IMAGING
PERFORMED BY**

Amanda Stewart

HOSPITAL NAME

Creditview Eglinton
Animal Hospital

REFERRING VET

Dr. Ghobrial

INVOICE

46599

DATE

1/28/26